


Anatomy and Physiology - Division C Exam

Duke University Science Olympiad Invitational 2020

January 18, 2020



Written by Sophia Velasco, University of Florida, B.S. Biochemistry 2023

Team Number: _____

Team Name: _____

Overall Score: _____/316

Ranking: _____

Instructions and Clarifications:

- You have **50** minutes to finish this exam.
- Each team may bring **one** 8.5" x 11" two-sided page of information in any form from any source and **two** non-programmable non-graphing calculators.
- You **may** split the exam but you are responsible for placing the exam in the proper order after the testing session.
- Anything written on the exam will **not** be graded. Only the **answer sheet** will be graded.
- Write your **team number** on every page of the **answer sheet**.
- There are **5** tiebreakers in this exam. They are denoted as **TB#**.
- If you have any questions or comments about the exam, feel free to reach me at velasco.scienceolympiad@gmail.com. **Happy testing!**



I. Integumentary System

Multiple Choice Directions: Choose the most appropriate answer for each question below. Each question is worth **one** point. **(20)**

1. Which of the following statements about the integumentary system is correct?
 - a. The dermis is avascular.
 - b. The subQ layer is part of the skin.
 - c. The epidermis is composed of nonkeratinized stratified squamous epithelium.
 - d. Langerhans cells arise from the red bone marrow and migrate to the epidermis.
 - e. None of the above

2. What cells in the skin are the least numerous of the epidermal cells?
 - a. Keratinocytes
 - b. Melanocytes
 - c. Langerhans cells
 - d. Merckel cells
 - e. None of the above

3. What cells in the skin develop from the ectoderm of a developing embryo and produce a pigment that absorbs UV light?
 - a. Keratinocytes
 - b. Melanocytes
 - c. Langerhans cells
 - d. Merkel cells
 - e. None of the above

4. What stratum of the epidermis contains stem cells that undergo mitosis to produce new keratinocytes?
 - a. Stratum granulosum
 - b. Stratum basale
 - c. Stratum corneum
 - d. Stratum lucidum
 - e. None of the above

5. What stratum of the epidermis is only present in thick skin?
 - a. Stratum corneum
 - b. Stratum granulosum
 - c. Stratum lucidum
 - d. Stratum basale
 - e. None of the above



6. Which of the following statements about the dermis is correct?
 - a. The dermis is composed of dense irregular connective tissue containing collagen and elastic fibers.
 - b. The dermis does not recoil easily.
 - c. The dermis is thinner than the epidermis.
 - d. There are no hair follicles embedded in the dermal layer.
 - e. None of the above

7. Which of the following statements about the papillary layer is correct?
 - a. The papillary layer makes up about $\frac{2}{3}$ of the thickness of the dermis.
 - b. The papillary layer contains thick collagen.
 - c. The papillary layer contains coarse elastic fibers.
 - d. The papillary layer does not contain Meissner corpuscles.
 - e. None of the above

8. Which of the following statements about the reticular layer is correct?
 - a. The reticular region is above the papillary layer.
 - b. The reticular region contains thick collagen fibers.
 - c. There are no fibroblasts in this region.
 - d. There are no macrophages in this region.
 - e. None of the above

9. In what stratum of the skin is carotene found?
 - a. Stratum basale
 - b. Stratum granulosum
 - c. Stratum corneum
 - d. Stratum lucidum
 - e. None of the above

10. What part of a hair is composed of 2-3 rows of irregularly shaped cells that contain large amount of pigments in dark hair?
 - a. Medulla
 - b. Cuticle
 - c. Cortex
 - d. Bulb
 - e. None of the above

11. What skin gland has a secreting portion in the dermis and usually opens into the neck of a hair follicle?
 - a. Sebaceous glands
 - b. Apocrine gland
 - c. Eccrine gland
 - d. Ceruminous gland
 - e. None of the above



12. Which of the following statements about an eccrine gland is correct?
- Eccrine glands are less common than apocrine glands.
 - Eccrine glands are mostly located in the skin of the forehead, palms and soles.
 - The secretory portion of an eccrine gland is located mostly in the epidermis.
 - There are plenty of eccrine glands in the nail beds of the fingers.
 - None of the above
13. What part of a nail is the skin below the nail plate?
- Nail root
 - Eponychium
 - Lunula
 - Nail bed
 - None of the above
14. What part of a nail is the visible portion of the nail?
- Nail body
 - Nail bed
 - Lunula
 - Nail matrix
 - None of the above
15. Which of the following statements about the function of the skin is correct?
- The skin is not a blood reservoir.
 - The oily sebum keeps the hairs of the skin dry.
 - About 1 L of water evaporates from the skin daily.
 - The skin can absorb vitamins A, D, E and K.
 - None of the above
16. Which mechanoreceptor responds to light touch?
- Meissner corpuscles
 - Ruffini endings
 - Merkel discs
 - Pacinian corpuscles
 - None of the above
17. Which mechanoreceptor detects vibrations of about 200-300 Hz?
- Meissner corpuscles
 - Ruffini endings
 - Merkel discs
 - Pacinian corpuscles
 - None of the above



18. Which of the following mechanoreceptors have small receptive fields and can make sustained responses to static stimulation?
- a. SA1
 - b. SA2
 - c. RA
 - d. Vater-Pacinian corpuscles
 - e. None of the above
19. Which of the following statements regarding Lamellar corpuscles is correct?
- a. It is smaller than Merkel cells.
 - b. There are more Lamellar corpuscles than Meissner's corpuscles.
 - c. The entire corpuscle has a layer of connective tissue surrounding it.
 - d. Most of the fibrous connective tissue in the capsule is made of Type I and Type III collagen network.
 - e. None of the above
20. Which of the following statements about Ruffini corpuscles is correct?
- a. It is a fast adapting mechanoreceptor.
 - b. There are no Ruffini corpuscles in cutaneous tissue between the dermal papillae and the hypodermis.
 - c. There are Ruffini corpuscles in deeper layers of the skin.
 - d. These receptors respond to light touch.
 - e. None of the above



Short Answer Directions: Answer the questions below with the most appropriate term. Complete sentences are **not** required for this section. Each question is worth **one** point. **(10)**

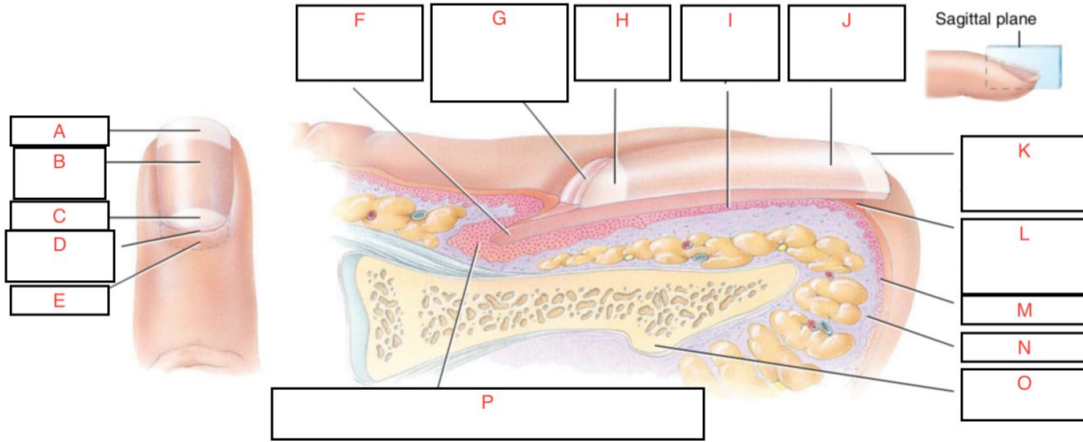
1. What is the term for the small, nipple-shaped structures that project into the undersurface of the epidermis?
2. What is the name of the process where cells move from one epidermal layer to the next then accumulate more keratin?
3. What pigment is derived from tyrosine in the presence of an enzyme called tyrosinase?
4. What pigment gives lighter-skinned individuals a skin color ranging from pink to red?
5. What is the term for the dense dermis surrounding the hair follicle?
6. What part of a hair contains areolar connective tissue and many blood vessels that nourish the growing hair follicle?
7. What type of hair is short, fine, pale and is barely visible to the naked eye?
8. What skin gland produces a waxy lubricating secretion in the external ear?
9. What is the term for the secretion of a ceruminous gland?
10. What part of a nail is the portion of the epithelium proximal to the nail root?

Pathology Part I: Answer the following questions about **psoriasis**. Each question is worth one point unless otherwise stated. **(14)**

1. What is the term for psoriatic skin changes at the spot of a skin injury? (2) **TB#1**
2. What type of psoriasis makes up about 90% of cases? (2)
3. What type of psoriasis occurs when the rash becomes very widespread? (2)
4. What is another term for inverse psoriasis? (2)
5. List one possible treatment for this disease.
6. What color is the rash associated with this disease?
7. **True or False:** This disease is autoimmune.
8. **True or False:** Identical twins are more likely to be affected by psoriasis than non-identical twins.
9. **True or False:** This disease is contagious.
10. **True or False:** There is no cure for psoriasis.



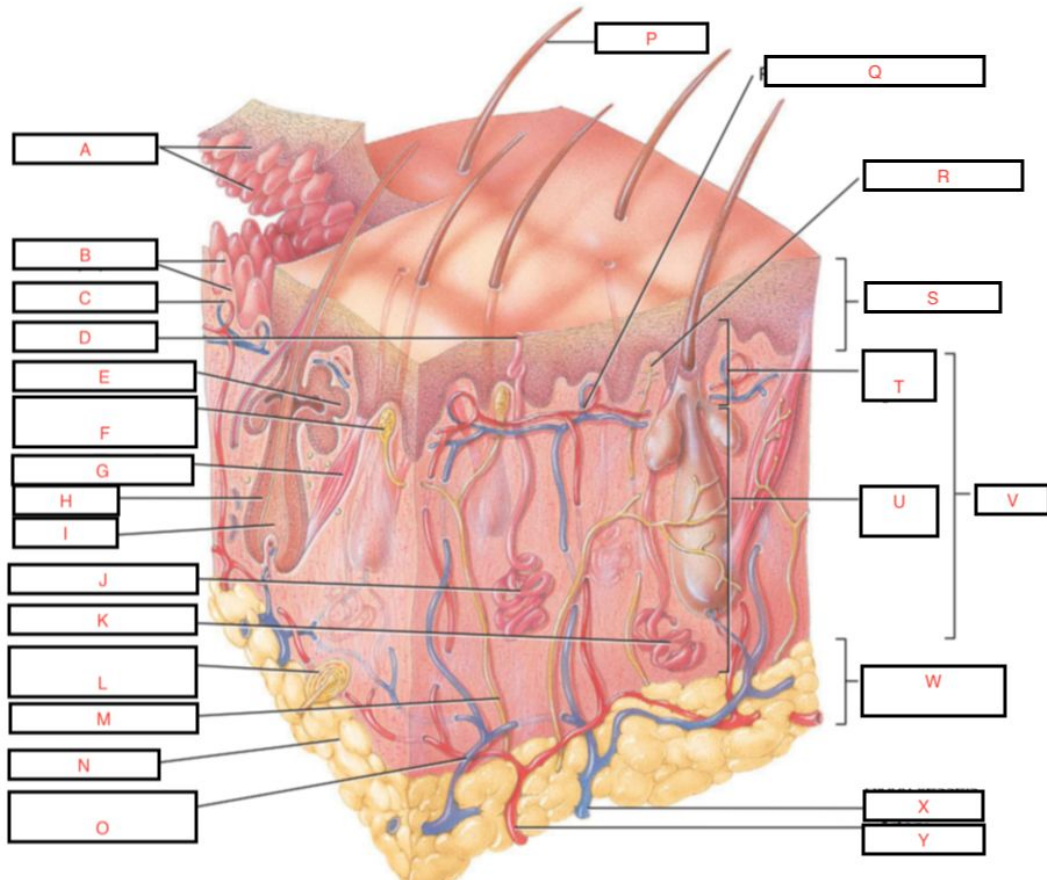
Labeling: Label the diagrams below. Each letter is worth **one** point. **(41)**



1.

(a) Dorsal view

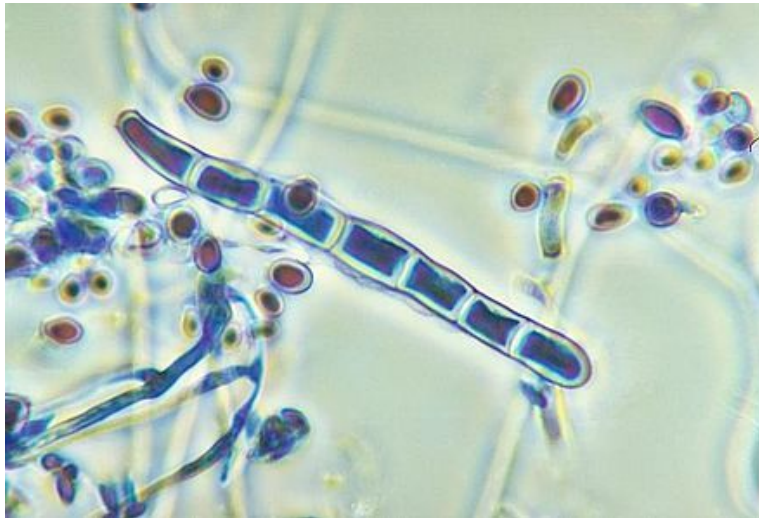(b) Sagittal section showing internal detail



2.



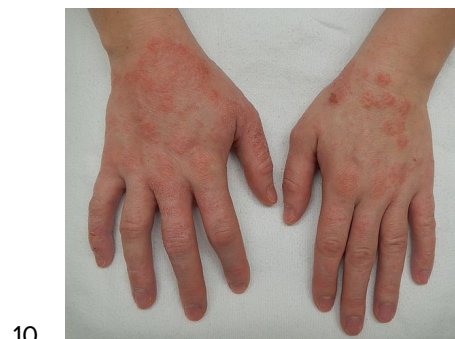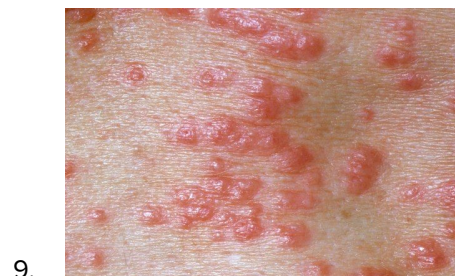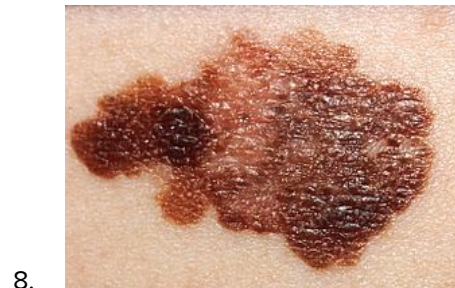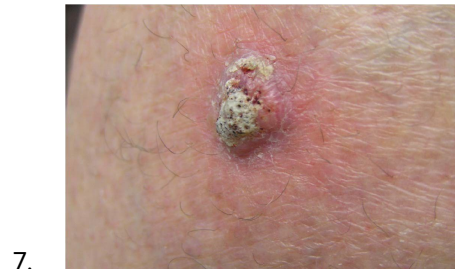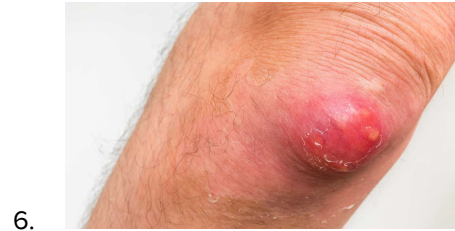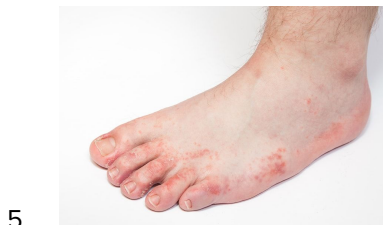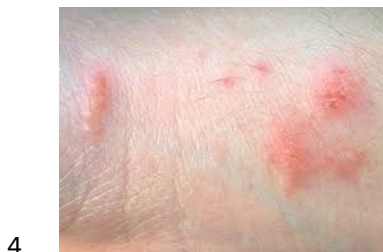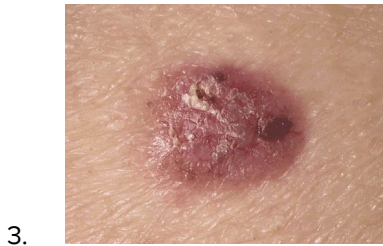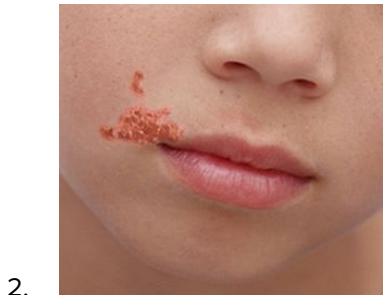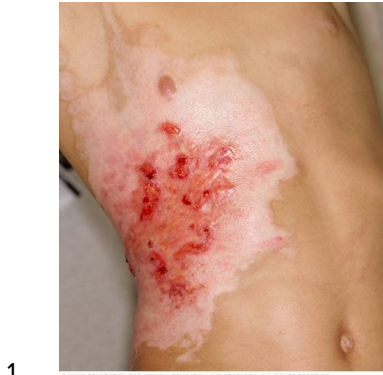Diagram-based Questions: Use the given diagram to answer the given questions. Each question is worth one point unless otherwise stated. **(11) TB#2**



1. What is the genus of the organism shown in the image? (2)
2. What disease can this organism cause?
3. List the genus of a different organism that can cause the disease addressed in question 2. (2)
4. **True or False:** There are no blisters associated with this disease addressed in question 2.
5. What part of the body does this organism most commonly grow?
6. **True or False:** Females are more affected by the disease caused by this organism than males.
7. **True or False:** Azoles are more effective than allylamines in treating the disease addressed in question 2.
8. **True or False:** Miconazole nitrate can be used to treat the disease addressed in question 2.
9. What percent of the population is affected by the disease addressed in question 2?
10. List one symptom associated with the disease addressed in question 2.



Pathology Part II: Based on the pictures below, determine what disease is shown. Be as **concise and specific** as possible. Complete sentences are **not** required for this section. Each picture is worth **one** point. **(10)**





II. Skeletal System

Multiple Choice Directions: Choose the most appropriate answer for each question below. Each question is worth **one** point. **(20)**

1. What part of a long bone is the region between the diaphysis and epiphysis?
 - a. Articular cartilage
 - b. Periosteum
 - c. Medullary cavity
 - d. Endosteum
 - e. None of the above

2. What part of a long bone is a tough connective tissue sheath and its associated blood supply that surrounds the bone surface wherever it is not covered by articular cartilage?
 - a. Diaphysis
 - b. Epiphyses
 - c. Periosteum
 - d. Endosteum
 - e. None of the above

3. What cells are unspecialized bone stem cells derived from mesenchyme?
 - a. Osteoprogenitor cells
 - b. Osteoblasts
 - c. Osteocytes
 - d. Osteoclasts
 - e. None of the above

4. What cells are huge cells that is a result of the fusion of as many as 50 monocytes?
 - a. Osteoprogenitor cells
 - b. Osteoblasts
 - c. Osteocytes
 - d. Osteoclasts
 - e. None of the above

5. What part of compact bone tissue are circular plates of mineralized extracellular matrix of increasing diameter that surrounds a network of blood vessels and nerves?
 - a. Osteons
 - b. Haversian canal
 - c. Concentric lamellae
 - d. Lacunae
 - e. None of the above



6. Which of the following statements about spongy bone tissue is correct?
 - a. Spongy bone tissue contains osteons.
 - b. Spongy bone consists of lamellae that are arranged in a regular pattern of thick columns called trabeculae.
 - c. There are macroscopic spaces in spongy bone tissue that consists of yellow bone marrow.
 - d. Spongy bone tissue makes up most of the interior bone tissue of short, flat, sesamoid, and irregularly shaped bones.
 - e. None of the above

7. What type of bone fracture consists of one end of the fractured bone being forcefully driven into the interior of the other?
 - a. Compound
 - b. Comminuted
 - c. Greenstick
 - d. Impacted
 - e. None of the above

8. Which of the following statements about aging and bone tissue is correct?
 - a. More bone tissue is produced than lost during bone remodeling in the elderly.
 - b. There is a decrease in bone mass in women after menopause.
 - c. Once bone mass begins in females, about 13% of bone mass is lost every 10 years.
 - d. Brittleness is a result of an increased rate of protein synthesis.
 - e. None of the above

9. What vitamin is needed for the synthesis of collagen?
 - a. A
 - b. C
 - c. D
 - d. K
 - e. None of the above

10. How many bones are in the axial skeletal system?
 - a. 78
 - b. 79
 - c. 80
 - d. 81
 - e. None of the above

11. How many bones are in the appendicular skeletal system?
 - a. 126
 - b. 127
 - c. 128
 - d. 129
 - e. None of the above



12. What type of bone is generally thin and composed of two nearly parallel plates of compact bone tissue enclosing a layer of spongy bone tissue?
- Short
 - Flat
 - Irregular
 - Sutural
 - None of the above
13. What type of vertebrae does not have an articular facet for ribs?
- Cervical
 - Thoracic
 - Lumbar
 - Two of the above
 - None of the above
14. What type of vertebrae has one vertebral and two transverse foramina?
- Cervical
 - Thoracic
 - Lumbar
 - Two of the above
 - None of the above
15. What type of vertebrae has the thickest size of intervertebral discs?
- Cervical
 - Thoracic
 - Lumbar
 - Two of the above
 - None of the above
16. Which of the following statements about articular cartilage is correct?
- It is independent of the molecular composition of the ECM.
 - There is no proteoglycan in the ECM of articular cartilage.
 - Most of the collagen is type III.
 - The articular cartilage of the patella is the thinnest.
 - None of the above
17. Which of the following statements about the pathophysiology of osteoarthritis is correct?
- It causes gross cartilage loss.
 - The morphology of the affected joint is not affected.
 - The collagen matrix becomes more organized in osteoarthritis.
 - There is a gain of proteoglycans in osteoarthritis.
 - None of the above



18. Which of the following forms the calvaria?
- a. Upper areas of the cranial bones
 - b. Lower areas of the cranial bones
 - c. Both A and B
 - d. Membranous viscerocranium
 - e. None of the above
19. Which of the following is a bone not joined to others by a suture?
- a. Occipital bone
 - b. Temporal bone
 - c. Ethmoid bone
 - d. Parietal bone
 - e. None of the above
20. How many parietal bones are there in the human body?
- a. 1
 - b. 2
 - c. 3
 - d. 4
 - e. None of the above



Short Answer Directions: Answer the questions below with the most appropriate term. Complete sentences are **not** required for this section. Each question is worth **one** point. **(10)**

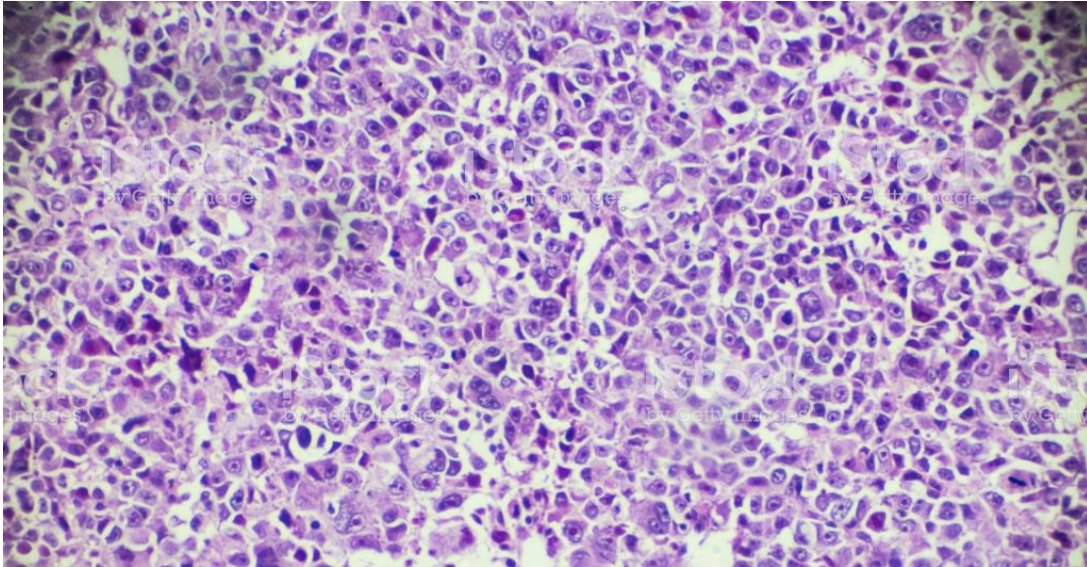
1. What is the term for a cartilaginous joint that has hyaline cartilage as its connecting material?
2. What type of fibrous joint is a substantial sheet of dense irregular connective tissue that binds neighboring long bones and permits amphiarthrosis?
3. What type of fibrous joint that has a greater distance between the articulating surfaces and more dense irregular connective tissue than in a suture?
4. What is the term for the hyaline cartilage that covers the bones in a synovial joint?
5. What sleeve-like structure surrounds a synovial joint, encloses the synovial cavity, and unites the articulating bones?
6. What is the term for a sac-like structure that is situated to alleviate friction in the shoulder and knee joints?
7. What is the term for a structure that wrap around certain tendons that experience friction as they pass through tunnels formed by connective tissue and bone?
8. What type of movement is a simple movement in which nearly flat bone surfaces move back-and-forth and from side-to-side with respect to one another?
9. What is the movement of bone away from the midline?
10. What is the movement of bone toward the midline?

Pathology Part I: The following statements below are descriptions of the diseases of the skeletal system. Determine what the disease is described. Be as concise and specific as possible. Complete sentences are **not** required for this section. **(8)**

1. The three types of this condition is idiopathic, congenital and neuromuscular. The idiopathic version of this disease is the most common.
2. A disease in which the density and quality of bone are reduced.
3. A tear of the ligament that connects the femur to the tibia, and there is a distinctive popping sound heard due to this injury.
4. A break in the bone.
5. A condition where a portion of a nucleus pushes through the crack in the annulus.
6. A disease that occurs when the protective cartilage that cushions the ends of bones wears down overtime.
7. A tear of the ligaments in the knee without a popping sound.
8. A condition where the spine is curved sideways that often occurs during the growth spurt before puberty.



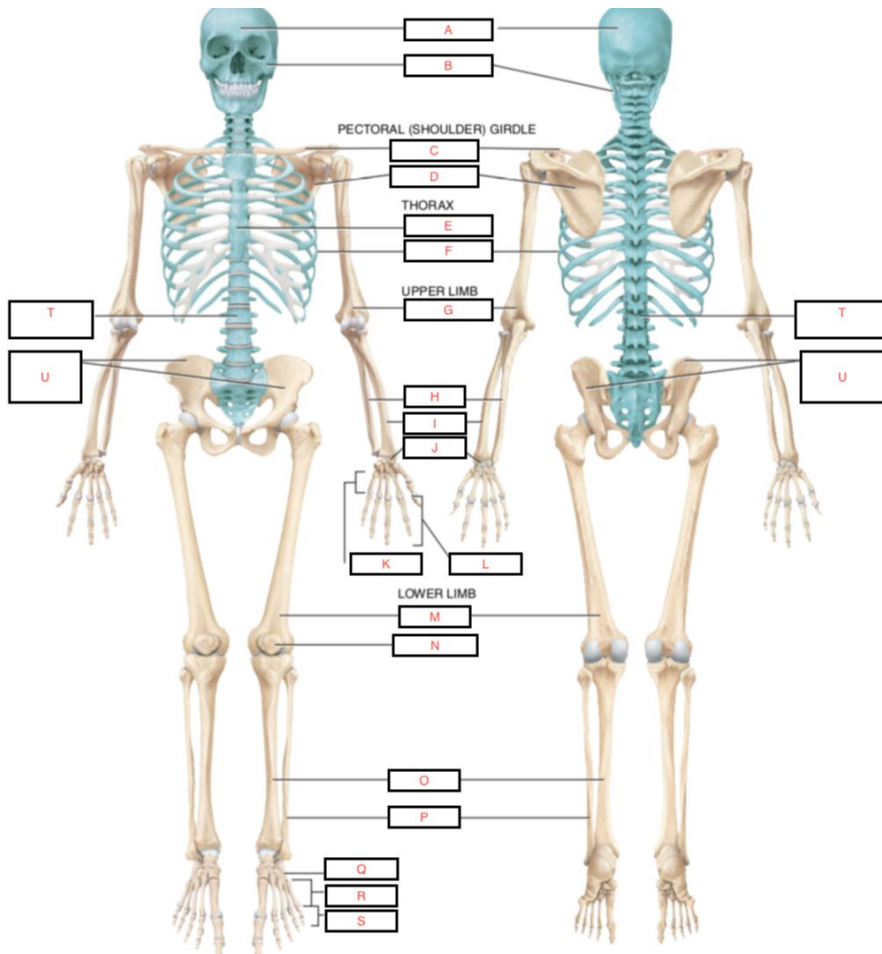
Pathology Part II: Use the given diagram to answer the given questions. Each question is worth one point unless otherwise stated. **(13) TB#3**



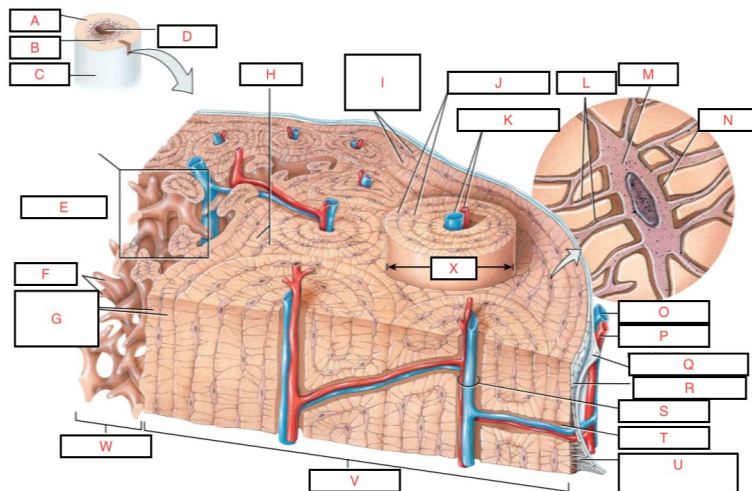
1. What disease is shown in the image?
2. The deletion of what chromosome is associated with a high risk of getting this disease? (2)
3. **True or False:** Germline TP53 mutation is associated with the development of this disease.
4. What part of the body does this disease most commonly occur in?
5. What part of the body is affected in 60% of the cases of this disease?
6. What is the term for right angles that form from tumor spicules of calcified bone? (2)
7. Microscopically, what is the most characteristic feature of this disease? (2)
8. The prognosis for this disease is separated into how many stages?
9. In what prognosis stage is this disease rare and has a prognosis of >90%?
10. In what prognosis stage is there a 40% five-year survival prognosis?



Labeling: Label the diagrams below. Each letter is worth **one** point. **(45)**



1.



2.



III. Muscular System

Multiple Choice Directions: Choose the most appropriate answer for each question below. Each question is worth **one** point. **(20)**

1. Which of the following statements about skeletal muscle tissue is correct?
 - a. Skeletal muscles are not striated.
 - b. Skeletal muscle tissue works mainly in an involuntary matter.
 - c. Some skeletal muscle is controlled involuntary.
 - d. There are only dark protein bands present in skeletal muscle tissue when examined using a microscope.
 - e. None of the above

2. Which of the following statements about cardiac muscle tissue?
 - a. Cardiac muscle is striated.
 - b. The action of cardiac muscle is voluntary.
 - c. The contraction and relaxation of cardiac muscle tissue is voluntary.
 - d. The AV node is the natural pacemaker of cardiac muscle tissue.
 - e. None of the above

3. Which of the following statements about smooth muscle tissue is correct?
 - a. Smooth muscle tissue is striated.
 - b. There are no smooth muscle tissue in the airways.
 - c. Smooth muscle tissue is controlled voluntarily.
 - d. The autonomic nervous system does not control smooth muscle tissue.
 - e. None of the above

4. What part of a skeletal muscle fiber tunnel in from the surface toward the center of each muscle fiber?
 - a. Sarcolemma
 - b. T tubules
 - c. Sarcoplasm
 - d. Myoglobin
 - e. None of the above

5. What component of a sarcomere is the lighter, less dense area that contains remainder of thin filaments but no thick filaments?
 - a. Z discs
 - b. A band
 - c. I band
 - d. H zone
 - e. None of the above



6. What component of a sarcomere is the narrow region in the center of each A band that contains thick filaments but no thin filaments?
 - a. Z discs
 - b. I band
 - c. H zone
 - d. M line
 - e. None of the above

7. What muscle protein is the main component of thick filaments and functions as a motor protein in all types of muscle tissue?
 - a. Myosin
 - b. Actin
 - c. Troponin
 - d. Tropomyosin
 - e. None of the above

8. What level of organization within a skeletal muscle consists of threadlike contractile elements within the sarcoplasm of a muscle fiber that extends the entire length of fiber?
 - a. Fascicle
 - b. Myofilaments
 - c. Muscle fiber
 - d. Myofibril
 - e. None of the above

9. Which of the following statements about muscle contraction is correct?
 - a. The contraction cycle repeats as the actin ATPase hydrolyzes the newly bound molecule of ATP.
 - b. Each of the 600 cross-bridges in one thin filament attaches and detaches about five times per second.
 - c. As the contraction cycle continues, movement of cross-bridges applies the force that draws the Z discs away from each other.
 - d. During a maximal muscle contraction, the distance between two Z discs can decrease to half the resting length.
 - e. None of the above

10. Which of the following statements about contraction coupling is correct?
 - a. A decrease in Ca^{2+} contraction in the sarcoplasm starts muscle contraction.
 - b. When a muscle fiber is relaxed, the concentration of Ca^{2+} in its sarcoplasm is very high.
 - c. The sarcoplasmic reticulum contains Ca^{2+} active transport pumps that use ATP to move Ca^{2+} constantly from the sarcoplasm into the sarcoplasmic reticulum.
 - d. Ca^{2+} flow move faster when transported back into the pumps than moving back into the sarcoplasmic reticulum.
 - e. None of the above



11. What is the general term for the chemical messenger released in the neuromuscular junction?
 - a. Neurotransmitter
 - b. Axon terminal
 - c. Junctional fold
 - d. Synaptic cleft
 - e. None of the above

12. What is the neurotransmitter released at the neuromuscular junction?
 - a. GABA
 - b. ACh
 - c. Dopamine
 - d. Serotonin
 - e. None of the above

13. Which of the following statements about microscopic anatomy of smooth muscle is correct?
 - a. A single relaxed smooth muscle fiber 30-200 micrometers long.
 - b. There are three nuclei within each fiber of a smooth muscle.
 - c. Smooth muscle fibers do not contain intermediate filaments.
 - d. The thick filaments of smooth muscle fibers attach to dense bodies.
 - e. None of the above

14. Which of the following statements about second-class levers is correct?
 - a. They produce a mechanical disadvantage.
 - b. The load is always closer to the fulcrum than the effort.
 - c. This adjustment contributes to speed and range of motion for force.
 - d. Second-class levers operate like a wheelbarrow.
 - e. None of the above

15. What arrangement of fascicles is nearly parallel to the longitudinal axis of muscle?
 - a. Triangular
 - b. Fusiform
 - c. Circular
 - d. Pennate
 - e. None of the above

16. Which of the following occurs at the neuromuscular junction in myasthenia gravis?
 - a. Antibodies are created against AchR in 0-10% of MG cases.
 - b. Antibodies are created against MuSK in 80% of MG cases.
 - c. A and B
 - d. There is a low density lipoprotein receptor-related protein 4 targeted by IgG1 in seronegative MG.
 - e. None of the above



17. Which of the following statements about the neuromuscular junction is correct?
- a. It is formed between a motor neuron and a muscle fiber.
 - b. The central and peripheral nervous system are not linked at this junction.
 - c. Synaptic transmission ends when an action potential reaches the presynaptic terminal of a motor neuron.
 - d. Disease associated with this junction can only be autoimmune.
 - e. None of the above
18. What correctly describes the pathophysiology of carpal tunnel syndrome?
- a. The flexor pollicis brevis becomes stronger due to the compression of the median nerve.
 - b. The opponens pollicis becomes stronger due to the compression of the median nerve.
 - c. There is a heightened sensation in the digits supplied by the median nerve.
 - d. The compression of the median nerve leads to the atrophy of the thenar eminence.
 - e. None of the above
19. Which of the following is conditions associated with carpal tunnel syndrome?
- a. Rheumatoid arthritis
 - b. Hyperthyroidism
 - c. Low progesterone levels
 - d. Homozygous mutations in SH3TC2
 - e. None of the above
20. What correctly describes the pathophysiology of fibromyalgia?
- a. There is only an abnormality in the ascending pathway involved in pain processing.
 - b. 50% less stimulus is necessary to evoke pain in individuals with this disease.
 - c. A proposed mechanism for the pathophysiology of fibromyalgia is a decrease in the release of proinflammatory cytokines.
 - d. A proposed mechanism for the pathophysiology of fibromyalgia is a decrease in the release of proinflammatory nitric oxide.
 - e. None of the above



Short Answer Directions: Answer the questions below with the most appropriate term. Complete sentences are **not** required for this section. Each question is worth **two** points. **(20) TB#4**

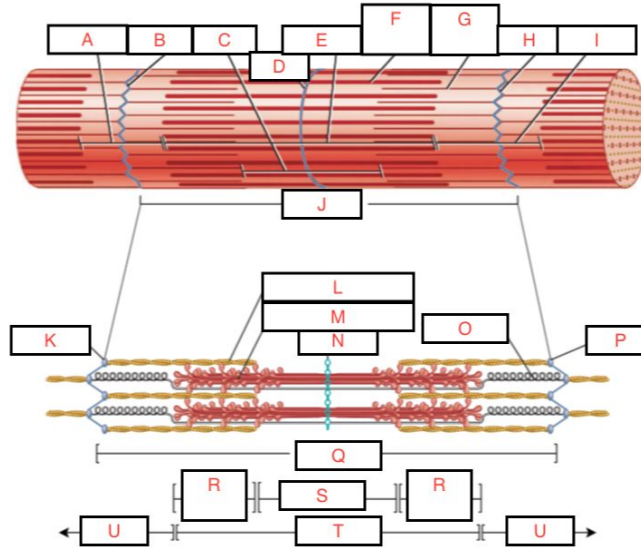
1. What is the origin of the orbicularis oris?
2. What is the insertion of the zygomaticus major?
3. What is the action of the masseter?
4. What is the insertion of the internal intercostals?
5. What is the origin of the teres major?
6. What is the action of the triceps brachii?
7. What is the origin of the flexor carpi radialis?
8. What is the insertion of the flexor digitorum superficialis?
9. What is the action of the extensor carpi ulnaris?
10. What is the origin of the tensor fasciae latae?

Classification: Determine what type of muscle contraction is addressed in the descriptions below. Each question is worth **one** point. **(10)**

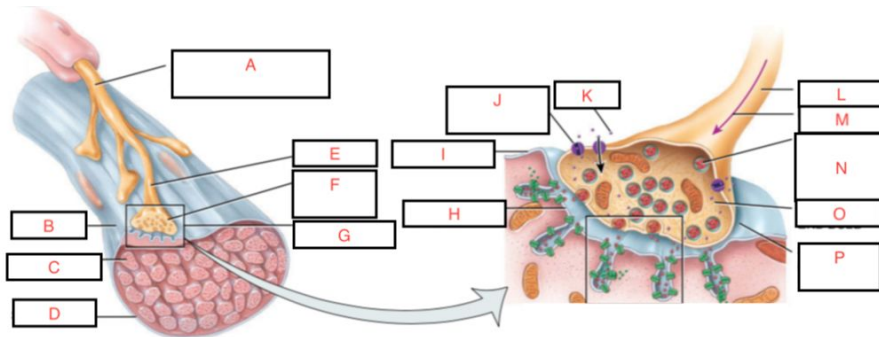
1. Tension generated is not enough to overcome the external load on the muscle and muscle fibers lengthen as they contract
2. This type of contraction can lead to more muscle damage than concentric loading
3. A bicep curl is an example of this muscle contraction type
4. Constant tension in the muscle despite changes in muscle length
5. Type of contraction that occurs when force generated by muscle exceeds load opposing its contraction
6. Muscle decelerates the joint at the end of a movement
7. Type of contraction that occurs when a muscle's force of contraction matches total load on the muscle
8. Muscle tension overcomes the load and shortens as it contracts
9. These contractions are called negatives in weight training
10. Contraction generates tension without changes in length



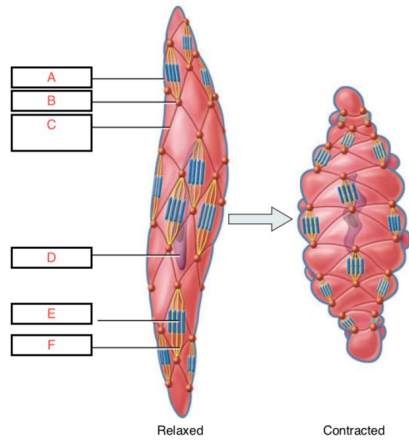
Labeling: Label the diagrams below. Each letter is worth **one** point. **(42)**



1.



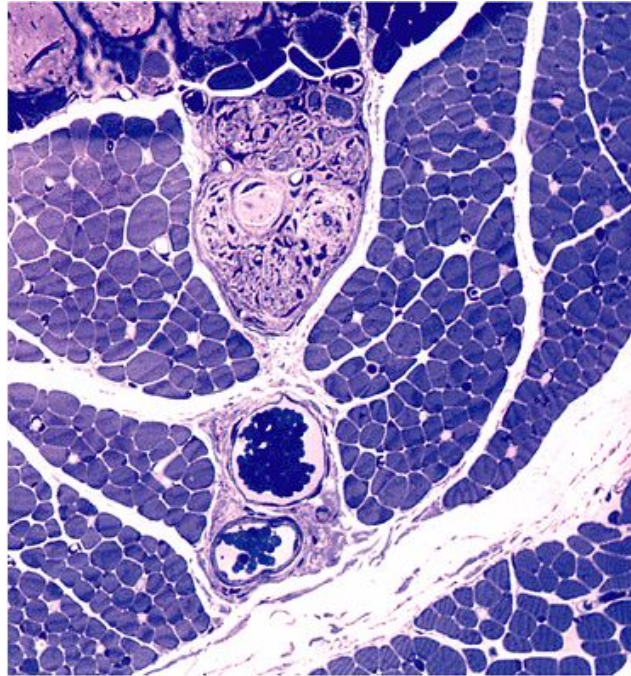
2.



3.



Diagram-based questions: Use the given diagram to answer the given questions. Each question is worth one point unless otherwise stated. **(14) TB#5**



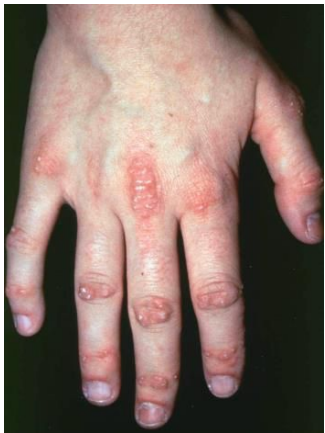1. What structure is seen in the given image? (2)
2. What is the role of this structure?
3. Where is this structure located in the body? (2)
4. What is the term for the braided strands of collagen seen in the body of this organ? (2)
5. **True or False:** The collagen strands in question 4 is more compact than in the tendon and is not encapsulated.
6. What happens to the sensory terminals when the muscle generates force?
7. What structure synapses with interneurons within the spinal cord that also project to the cerebellum and cerebral cortex? (2)
8. **True or False:** Ib input inhibits motoneurons of the receptor-bearing muscles during locomotion.
9. **True or False:** The ascending pathways to the cerebellum is only the dorsal spinocerebellar tract.
10. What happens to the terminals of Ib afferent axons when there is stretching?



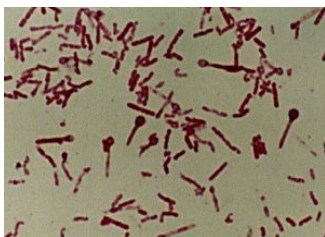Pathology Part I: Match the following symptoms with the corresponding disease of the muscular system. Each question or picture is worth **one** point. **(4)**

1. Fever, sore throat, headache, vomiting, fatigue, back pain or stiffness, neck pain or stiffness, pain of stiffness in the arms of legs, muscle weakness or tenderness, loss of reflexes, severe muscle aches or weakness, flaccid paralysis
2. Frequent falls, difficulty rising from a lying or sitting up position, trouble running or jumping, waddling gait, walking on toes, large calf muscles, muscle pain and stiffness, learning disabilities
3. Trouble talking, problems walking up the stairs or lifting objects, facial paralysis, difficulty breathing, difficulty swallowing, difficulty chewing, fatigue, hoarse voice, drooping of eyelids, double vision
4. Jaw cramping, muscle spasms, painful muscle stiffness all over the body, trouble swallowing, seizures, headache, fever, sweating, changes in blood pressure, tachycardia

Pathology Part II: Determine what disease is shown based on the pictures given. The pictures may show diseases or a pathogen associated with the disease. Each question or picture is worth **one** point. **(4)**



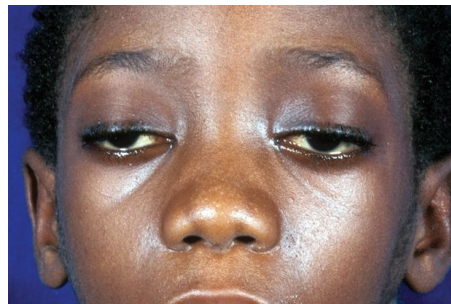
5.



6.



7.



8.